

**CONTRA COSTA PATHOLOGY ASSOCIATES**

399 Taylor Blvd, Suite 200, Pleasant Hill, CA 94523  
Phone: (925) 270-3575 Fax: (925) 270-3589  
Website: www.cocopath.net



Medical Director: Nader Shihabi, M.D.  
Nicholas Byrne, M.D. Barry Latner, M.D.  
Christine Cesca, M.D.  
Jeffrey Curtis, M.D. Dennis Hwang, M.D.  
Risha Ramdall, M.D.

**CoCoPATH**

**Patient: SAMPLE, REPORT**

**Age: 62 Sex: F DOB: 11/28/1952**

**Clinician: SAMPLE DERM REPORT**

123 Main Street

Suite #100

Pleasant Hill, CA 94523

**CCP#: 651318**

**Phone: (925) 111-2222**

**Fax: 925-222-1111**

**Case #: SP14-4377**

**Collected: 03/23/2015**

**Received: 03/23/2015**

**DERMATOPATHOLOGY REPORT**

**MICROSCOPIC DIAGNOSIS:**

**A. Skin, left cheek, biopsy:**

- Melanoma in situ

**B. Skin, right shoulder, biopsy:**

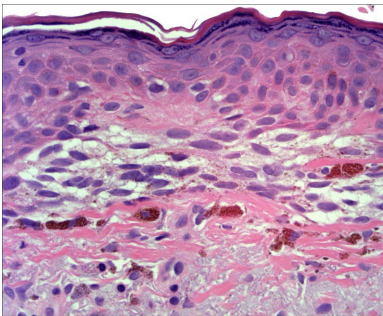
- Basal cell carcinoma, nodular type

**MICROSCOPIC DESCRIPTION:**

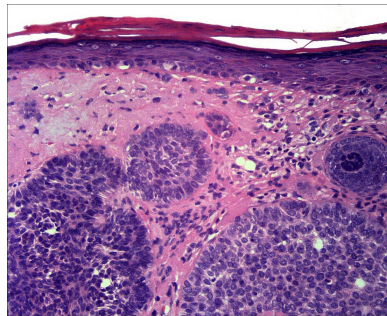
A. Sections demonstrate skin with a poorly circumscribed proliferation of atypical melanocytes at the dermal-epidermal junction arranged in a confluent lentiginous fashion with irregular nesting. Occasional pagetoid upward scatter is identified. There is no evidence of a dermal melanocytic component. There is a background of marked solar elastosis. The proliferation extends to the peripheral biopsy edges.

B. Sections demonstrate nests of basaloid epithelial cells arranged as nodular aggregates in the dermis. There is peripheral palisading of nuclei with a myxoid stroma. Stromal retraction from the nests is identified. The proliferation extends to the peripheral and deep biopsy edges.

**MICROSCOPIC IMAGES:**



A. Left cheek, melanoma in situ



B. Right shoulder, basal cell carcinoma

**GROSS DESCRIPTION:**

A. The specimen is received in formalin labeled with the patient's name and "left cheek" and consists of a 0.9 x 0.7 x 0.1 cm shave biopsy of skin with a flat brown surface. Submitted in toto.

B. The specimen is received in formalin labeled with the patient's name and "right shoulder" and consists of a 0.7 x 0.6 x 0.1 cm

**GROSS DESCRIPTION:** (continued)

shave biopsy of skin. Submitted in toto.

(CEC/cec)

---

**SPECIMEN:**

- A. Left cheek
- B. Right shoulder


**CLINICAL INFORMATION:**

- A. 1.2 cm irregular tan patch
- B. 0.8 cm pearly papule

**COPIES TO:**

SAMPLE DERM REPORT

**ELECTRONICALLY SIGNED:**



Christine E Cesca MD  
Pathologist  
(Case signed 03/25/2015 at 15:48)

***The specimen(s) is microscopically examined by a board-certified dermatopathologist at Contra Costa Pathology Associates, 399 Taylor Blvd #200, Pleasant Hill, CA, resulting in the histologic diagnosis.***

*Any included microscopic images are representative and for purposes of illustration only; they are not suitable for diagnostic use.*