



Patient: TEST, PATIENT
Age: 45 Sex: M DOB: 12/22/1971
Clinician: PHYSICIAN, TEST
5725 W LAS POSITAS BLVD SUITE 260
Pleasanton, CA 94588-4016

CCP#: 7373886
LMP:
Phone:
Fax: 555-5555

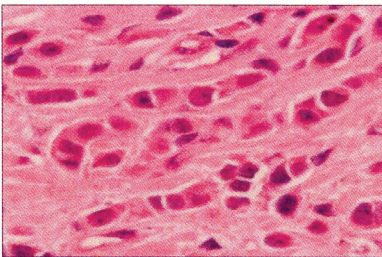
Case #: SP17-6
Collected: 03/22/2017
Received: 03/22/2017

GASTROINTESTINAL PATHOLOGY REPORT

MICROSCOPIC DIAGNOSIS:

- A. Sigmoid colon-
Sessile serrated adenoma
- B. Rectal polyp, biopsy:
Hyperplastic polyp.

MICROSCOPIC IMAGES:



Sigmoid

GROSS DESCRIPTION:

- A. The specimen is received in formalin labeled with the patient's name and "Sigmoid" and consists of a 2 mm aggregate of tan soft tissue. Submitted in toto in A.
- B. The specimen is received in formalin labeled with the patient's name and "Rectum" and consists of a 1 cm tan soft tissue. Submitted in toto in B.

(EC/ec)

SPECIMEN:

- A. Sigmoid Colon
B. Rectum

CLINICAL INFORMATION:

- A. 2 mm polyp
B. bx

COPIES TO:

PHILLIP A WOLFE/555-5555

ELECTRONICALLY SIGNED:

Erin Cronister
Pathologist
(Case signed 03/22/2017 at 11:40)

Related Cases

No history found

The specimen(s) is microscopically examined resulting in the histologic diagnosis. Examination performed at Contra Costa Pathology Associates, 399 Taylor Blvd #200, Pleasant Hill, CA. Any included microscopic images are representative and for purposes of illustration only; they are not suitable for diagnostic use.

SAMPLE REPORT